

## Serum YKL-40 is increased in patients with hepatic fibrosis

Julia S. Johansen<sup>1</sup>, Per Christoffersen<sup>4</sup>, Søren Møller<sup>3</sup>, Paul A. Price<sup>5</sup>, Jens H. Henriksen<sup>3</sup>,  
Charly Garbarsch<sup>6</sup> and Flemming Bendtsen<sup>2</sup>

Department of Medicine, <sup>1</sup>Division of Rheumatology and <sup>2</sup>Department of Gastroenterology, Medical Division, <sup>3</sup>Department of Clinical Physiology and Nuclear Medicine, <sup>4</sup>Department of Pathology, Hvidovre Hospital, and <sup>6</sup>Institute of Medical Anatomy Section A, The Panum Institute, University of Copenhagen, Denmark; <sup>5</sup>Department of Biology 0368, University of California, San Diego, La Jolla, CA, USA

**Background/Aims:** YKL-40, a mammalian member of the chitinase family, is a lectin that binds heparin and chitin. The function of YKL-40 is unknown, but it may function in tissue remodelling. The aims of this study were to assess the level of circulating YKL-40 in patients with various kinds and degree of chronic liver disease and its possible relation to liver fibrosis.

**Methods:** Serum YKL-40 levels were determined by radioimmunoassay in 129 patients with suspected liver disease and related to histological findings and immunohistochemical staining of YKL-40 in a liver biopsy taken simultaneously with the blood sample.

**Results:** The median serum YKL-40 was highest in patients with alcoholic cirrhosis (532 µg/l), in particular in patients with additional alcoholic hepatitis (740 µg/l). Patients with alcoholic cirrhosis, post-hepatitic cirrhosis (425 µg/l) and non-cirrhotic fibrosis (330 µg/l) had significantly higher serum YKL-40 than normal subjects (102 µg/l), patients with fatty liver (195 µg/l)

or patients with viral hepatitis without fibrosis (174 µg/l). Serum YKL-40 was significantly ( $p < 0.001$ ) related to the degree of liver fibrosis with the highest levels in patients with moderate (466 µg/l) to severe (676 µg/l) fibrosis. Serum YKL-40 was also increased ( $p = 0.018$ ) in patients with slight fibrosis (270 µg/l) compared to patients without fibrosis. Immunohistochemical analysis demonstrated positive staining for YKL-40 antigen in areas with fibrosis, particularly areas with active fibrogenesis. YKL-40 staining was never found in hepatocytes.

**Conclusions:** Our study indicates that the increased serum YKL-40 in patients with liver disease of various degree and aetiology seems to reflect fibrosis and fibrogenesis.

**Key words:** Alcoholic liver disease; HC gp-39; Liver fibrogenesis; Liver fibrosis; YKL-40.

HEPATIC fibrosis is a complex and dynamic process that involves activation of cells producing matrix material, changes in the extracellular matrix components and tissue remodelling (1). Conventional biochemical and serological tests are of little value for diagnosis of the degree of liver fibrosis and the activity of fibrogenesis, and percutaneous liver biopsy is therefore used to assess the extent of liver fibrosis and fibrogenesis (1,2). However, a liver biopsy is sometimes of questionable value because of the heterogeneous distribution of pathological changes in the liver. For years

there has been a search for biochemical or serological markers reflecting fibrotic processes in liver disease. Markers that detect patients with ongoing fibrosis at an early stage, before irreversible damage has developed, would be an important addition to the clinician's diagnostic and prognostic tools (1–3).

YKL-40<sup>§</sup> is a mammalian member of a chitinase family (family 18-glycosylhydrolases) (4–13). The physiological function of YKL-40 is not known, but the pattern of its expression in normal and diseased states suggests that it could function in remodelling of the extracellular matrix or in tissue inflammation (4–16). YKL-40 mRNA expression is found in human

Received 25 May; revised 8 November; accepted 15 November 1999

**Correspondence:** Julia S. Johansen, Department of Medicine, Division of Rheumatology 232, Hvidovre Hospital, University of Copenhagen, Kettegård Alle 30, DK-2650 Hvidovre, Denmark. Tel: 45 36322839. Fax: 45 36471410. e-mail: julia.johansen@post3.tele.dk

<sup>§</sup> The protein has been termed YKL-40 from its molecular weight (40 kDa) and the one letter code for its three N-terminal amino acids (tyrosine, lysine and leucine) (10).

liver (5). We have recently reported in a small study of patients with chronic liver disease that plasma YKL-40 is elevated in patients with chronic liver disease and may be related to the degree of liver fibrosis (17). Moreover, YKL-40 is released from the hepatosplanchnic system (17).

The purpose of the present study was to assess whether serum YKL-40 reflects the severity of liver fibrosis. We measured the serum levels of YKL-40, the aminoterminal propeptide of type III procollagen (PIIINP) and hyaluronan in patients with various liver diseases. We compared the serum YKL-40 values with histological changes in liver biopsies. Especially the degree of fibrosis and ongoing fibrogenesis was related to serum YKL-40 and to the degree of immunohistochemical YKL-40 staining in the liver biopsy.

## Materials and Methods

### Patients

The study included 129 biopsies from consecutive patients (82 men and 47 women with a median age of 49 years (range 24–80 years)) referred to the Department of Gastroenterology between December 1992 and November 1994 with suspicion of liver disease. A blood sample and a liver biopsy were taken simultaneously from each patient. Diagnosis of the liver disease was based on histology and accepted biochemical and clinical criteria. Four subjects did not have any signs of liver disease or other diseases; 16 patients had fatty liver; 31 patients had non-cirrhotic liver fibrosis (26 patients were alcoholics, one had severe obesity, one had been toxicated with halothane, and three had cryptogenic liver fibrosis); 51 patients had alcoholic cirrhosis; 17 patients had non-cirrhotic viral hepatitis (acute viral hepatitis type A ( $n=2$ ), chronic aggressive hepatitis or persistent hepatitis (type B virus ( $n=3$ ), type C virus ( $n=7$ ), both type B and C virus ( $n=5$ ))); and 10 patients had posthepatic cirrhosis (type B virus ( $n=2$ ), type C virus ( $n=2$ ), or both type B and C virus ( $n=6$ )). The main morphological diagnoses as well as pertinent clinical and biochemical parameters of the patients are summarised in Table 1. The collection of the material in the study was approved by the local ethics committee.

### Histological methods

All liver biopsies were performed percutaneously according to the Menghini technique, with a needle diameter of 1.6 mm (18). The biopsy material was divided, and one of the two parts was fixed in

neutral formalin and the other part was immediately frozen at  $-80^{\circ}\text{C}$ . The formalin-fixed tissue was embedded in Paraplast<sup>®</sup> and cut in 5- $\mu\text{m}$  thick serial sections (54 sections). The 129 biopsies from the 129 patients were assessed by two of the investigators (PC & JSJ) in close co-operation, without knowledge of clinical, biochemical or serological findings. PC is a specialist in pathology with special experience in liver pathology (19).

The following stainings were carried out on all biopsies: Hematoxylin-Eosin, Van Gieson-Hansen, PAS after diastase, Orcein, Gomori silver impregnation for reticulin fibres, Perl's stain and Methyl Green Pironin. The histological findings were assessed as previously described (19). For each biopsy, the degree of fibrosis was estimated semi-quantitatively and graded on a scale of 0–3: 0, representing no increase in any part of the biopsy; 1, questionable/minimal increase, i.e. enhanced connective tissue staining in the central part of the lobule with a few coarse perisinusoidal fibers present, but with a preserved architecture; 2, moderate increase, i.e. a distinct occurrence of pericellular and perisinusoidal coarse fibers eventually accompanied by a moderate portal and periportal fibrosis, but with preserved lobular architecture; and 3, severe increase with bridging fibrosis and with extensive portal and periportal fibrosis. In addition the occurrence of immature connective tissue in the border area between parenchyma and mature connective tissue, an indication for ongoing fibrogenesis, was semi-quantitatively graded on a scale of 0–3: 0, representing no occurrence of immature connective tissue; 1, slight; 2, moderate and 3, severe occurrence.

### Biochemical and serological methods

Serum samples, collected in the morning simultaneously with the liver biopsy, were stored at  $-20^{\circ}\text{C}$  until analysed. Routine biochemical tests (haemoglobin, serum alkaline phosphatase, serum aspartate aminotransferase, bilirubin, coagulation factors II, VII, X index, serum albumin and serum creatinine) were carried out with automated techniques (SMAC).

**YKL-40 assay:** Serum YKL-40 was determined by radioimmunoassay (RIA) using rabbit antibody raised against human YKL-40 as previously described (4). The intra- and inter-assay coefficients of variation were  $<6.5\%$  and  $<12\%$ , and the detection limit was 20  $\mu\text{g/l}$ . The median serum YKL-40 in 260 healthy adults, 144 females and 116 males, with a median age of 48 years (range 18–79 years) was 102  $\mu\text{g/l}$  (upper 95th percentile = 247  $\mu\text{g/l}$ ). Further details about these healthy adults are given elsewhere (20).

**PIIINP assay:** Serum PIIINP was measured by a commercially available RIA (Orion Diagnostica, Espoo, Finland) (21). The intra- and inter-assay coefficients of variation were 4.5% and 5.5%. The median serum PIIINP in 260 healthy adults (described above) was 3  $\mu\text{g/l}$  (upper 95th percentile = 5.4  $\mu\text{g/l}$ ).

**Hyaluronan assay:** Serum hyaluronan was measured by a commercially available radiometric assay (Pharmacia, Uppsala, Sweden) based on the use of specific hyaluronan-binding proteins isolated from

TABLE 1

Biochemical characteristics of the patients according to pathoanatomical diagnosis

Group	<i>n</i>	Age (years)	Serum ASAT (10–40 U/l) <sup>†</sup>	Serum AP (50–275 U/l) <sup>†</sup>	Serum bilirubin (3–17 $\mu\text{mol/l}$ ) <sup>†</sup>	Serum albumin (540–800 $\mu\text{mol/l}$ ) <sup>†</sup>	Factors (2,7,10) (0.7–1.3) <sup>†</sup>	Serum creatinine (49–121 $\mu\text{mol/l}$ ) <sup>†</sup>
Normal	4	39 (26–59)	58 (28–100)	323 (142–609)	15 (9–26)	644 (639–655)	0.96 (0.86–1.3)	78 (56–86)
Fatty liver	16	47 (28–62)	52 (18–326)	313 (153–1078)	8 (5–18)	547 (402–714)	1.12 (0.54–1.3)	70 (48–128)
Viral hepatitis	17	41 (24–64)	55 (8–800)	200 (134–655)	13 (6–212)	637 (479–729)	0.92 (0.50–1.3)	72 (56–95)
Non-cirrhotic fibrosis	31	49 (25–78)	59 (28–499)	265 (120–1299)	14 (4–46)	583 (234–741)	1.01 (0.56–1.3)	67 (46–113)
Post-hepatic cirrhosis	10	45 (26–80)	86 (42–249)	249 (139–1302)	9 (4–55)	608 (423–671)	0.93 (0.46–1.18)	67 (54–127)
Alcoholic cirrhosis	51	53 (30–74)	88 (22–1120)	372 (167–1672)	25 (6–233)	499 (328–694)	0.81 (0.38–1.3)	73 (34–566)

Values are median (range). ASAT=aspartate aminotransferase; AP=alkaline phosphatase. <sup>†</sup>=normal range.

bovine cartilage. The intra- and inter-assay coefficients of variation were 10% and 8%. The median serum hyaluronan in 247 healthy adults was 28  $\mu\text{g/l}$  (upper 95th percentile=97  $\mu\text{g/l}$ ) (22).

#### Immunohistochemical methods for YKL-40

Frozen samples of liver tissue were cut at 5  $\mu\text{m}$  and stained routinely with haematoxylin and eosin in order to establish that the tissue was well conserved and neighbouring sections were used for immunolocalization of YKL-40 antigen using specific antisera. Prior to immunostaining sections were methanol-fixed at  $-20^{\circ}\text{C}$  for 5 min. Conventional alkaline phosphatase staining technique for polyclonal antibodies was used as previously described (17). Briefly the following steps were included (all performed at room temperature): non-specific binding was blocked by incubation for 5 min with 4% bovine serum albumin (BSA) (Sigma A-4503) in Tris buffered saline (TBS); binding of primary antibody was performed for 30 min with an affinity-purified rabbit polyclonal IgG against human YKL-40 diluted in TBS containing 4% BSA (IgG concentration of the YKL-40 antibody was 66  $\mu\text{g/ml}$ ). Non-immune rabbit serum (Dako X936, Copenhagen, Denmark) was used as negative controls in the same IgG concentration of 66  $\mu\text{g/ml}$  in TBS containing 4% BSA. The slides were then washed 3 times with TBS and incubated for 30 min with alkaline phosphatase-conjugated swine antibodies to rabbit immunoglobulins (Dako D306) diluted 1:20 in TBS containing 4% BSA, washed twice in TBS and then incubated for 10 min with 0.05 M Tris/HCl, pH 7.6, washed twice with 0.2 M Tris-HCl, pH 9.5 and then incubated for 5 min with 0.75 mg/ml levamisol (Sigma L-9756) in 0.2 M Tris-HCl, pH 9.5. The slides were stained for 20 min with Sigma FAST™ BCIP/NBT tablets (Sigma B-5655) with 0.75 mg/ml levamisol in 0.2 M Tris-HCl, pH 9.5. The colour reaction was stopped by washing in running tap water and the slides were mounted in Glyccergel (Dako).

Each liver specimen was microscopically examined blindly and scored for the presence of YKL-40 expression in a scale as follows: score 0=no YKL-40 staining; score 1=scanty YKL-40 staining; and score 2=moderate to intense YKL-40 staining.

#### Statistical analysis

The statistical analyses were done with SigmaStat (SPSS, Chicago, IL, USA) and SAS® (SAS Institute, Cary, NC, USA). Results are given as median and range. Comparison between groups was performed by the non-parametric Mann-Whitney rank sum test or the

Kruskal-Wallis test for unpaired differences. Correlation analysis was based on the Spearman's rho test. *p*-values less than 0.05 were considered to be significant. In a multiple regression model serum YKL-40, PIIINP and hyaluronan were logarithmically transformed and related to the degree of liver fibrosis (treated as an ordinal variable with four categories) through a proportional odds regression model for ordinal data (23).

## Results

The individual concentrations of serum YKL-40, PIIINP and hyaluronan in relation to the various liver diseases, determined by histopathological and clinical criteria, are illustrated in Fig. 1 (a, b and c) and the median levels are given in Table 2. The serum YKL-40 levels were highest in patients with alcoholic liver cirrhosis (median 532  $\mu\text{g/l}$  and 5-fold increased compared with the median level of healthy age-matched controls), posthepatic cirrhosis (425  $\mu\text{g/l}$ ) and non-cirrhotic fibrosis (330  $\mu\text{g/l}$ ), and these serum YKL-40 levels were significantly ( $p<0.01$ – $p<0.001$ ) higher than serum YKL-40 values in age-matched controls (102  $\mu\text{g/l}$ ; upper 95th percentile=247  $\mu\text{g/l}$ ), in patients with fatty liver (195  $\mu\text{g/l}$ ), and in patients with chronic viral hepatitis without cirrhosis (174  $\mu\text{g/l}$ ). Multiple comparison between the different groups of patients with liver disease showed that patients with alcoholic cirrhosis had significantly higher serum YKL-40, PIIINP and hyaluronan concentrations than patients with non-cirrhotic fibrosis, viral hepatitis and fatty liver (Table 2) (Kruskal-Wallis one way ANOVA on ranks with Dunn's method:  $p<0.05$ ). A significant difference between alcoholic and posthepatic cirrhosis was only found in serum PIIINP levels.

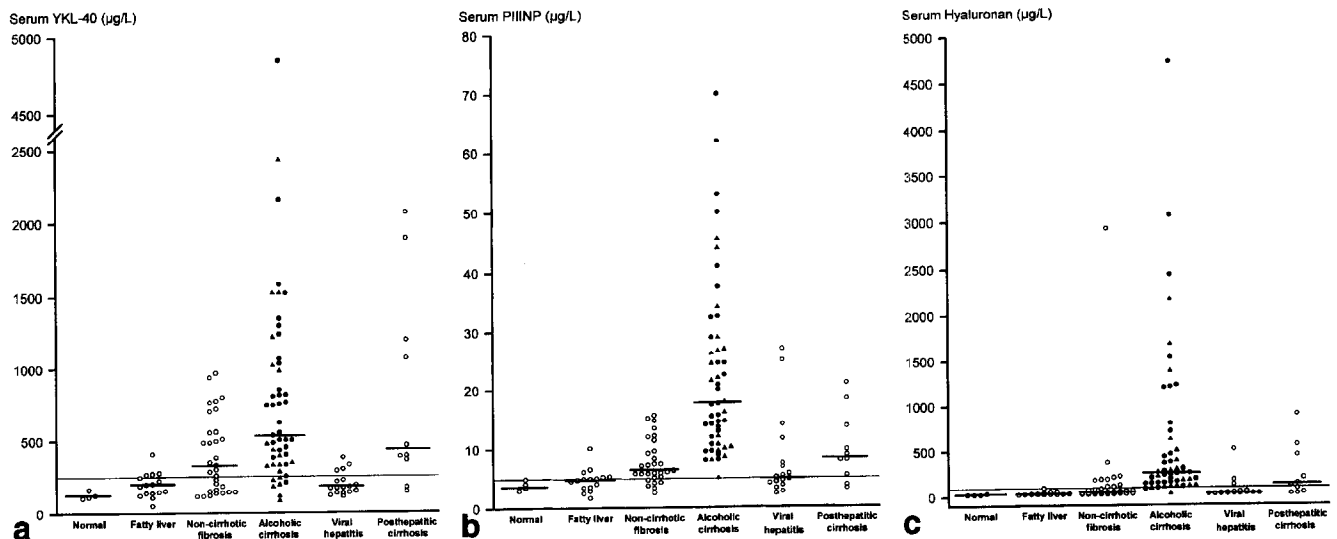


Fig. 1. Serum concentrations of YKL-40 (a), PIIINP (b) and hyaluronan (c) in patients with different liver diseases. The bars represent median values. The horizontal lines represent the upper limit (95th percentile) of the normal range of serum YKL-40 (247  $\mu\text{g/l}$ ), serum PIIINP (5.4  $\mu\text{g/l}$ ) and serum hyaluronan (97  $\mu\text{g/l}$ ). (●) patients with alcoholic cirrhosis in combination with alcoholic hepatitis and (▲) patients without alcoholic hepatitis. (○) all other patients.

TABLE 2

Serum YKL-40, PIIINP and hyaluronan concentrations in patients with different liver diseases

	Serum YKL-40 ( $\mu\text{g/l}$ )	Serum PIIINP ( $\mu\text{g/l}$ )	Serum hyaluronan ( $\mu\text{g/l}$ )
Normal	118* (105-165)	3.9* (3.0-5.0)	25* (25-36)
Fatty liver	195* (50-408)	4.9* (1.7-10.1)	26* (21-93)
Viral hepatitis	174* (111-380)	5.2* (2.4-27.0)	30* (25-508)
Non-cirrhotic fibrosis	330* (115-967)	6.4* (2.6-15.6)	54* (25-2920)
Posthepatic cirrhosis	425 (145-2070)	8.4* (3.2-21.0)	127 (25-894)
Alcoholic cirrhosis	532 (82-4850)	17.6 (5.1-70.0)	258 (30-4730)

Values are medians (range). PIIINP=N-terminal propeptide of type III procollagen. Kruskal-Wallis one-way ANOVA on ranks with multiple comparisons, Dunn's method: \* $p < 0.05$  vs. alcoholic cirrhosis.

Serum YKL-40 levels were significantly ( $p=0.014$ ) higher in the subset of patients with alcoholic cirrhosis who also had alcoholic hepatitis (median 740  $\mu\text{g/l}$ ; 30 of these 31 patients had elevated serum YKL-40 (i.e. above the upper 95th percentile level of the controls, i.e.  $>247 \mu\text{g/l}$ ) compared with patients with alcoholic cirrhosis without hepatitis (median 338  $\mu\text{g/l}$ ; 14 of these 20 patients had elevated serum YKL-40). No differences between these two patient groups were found in serum PIIINP (17.4 vs. 19.7  $\mu\text{g/l}$ ,  $p=0.7$ ) or serum hyaluronan (258 vs. 238  $\mu\text{g/l}$ ,  $p=0.3$ ). Sixteen (52%) of the 31 patients with alcoholic cirrhosis in combination with alcoholic hepatitis had severe fibrosis compared to only four (20%) of the patients with alcoholic cirrhosis without alcoholic hepatitis.

The individual concentrations of serum YKL-40, PIIINP and hyaluronan in relation to the degree of liver fibrosis defined histologically are illustrated in

Fig. 2 (a, b and c). All three biochemical parameters correlated with the degree of liver fibrosis (Spearman's rank correlation,  $p < 0.001$ ). The serum concentration of YKL-40 was highest in patients with severe fibrosis (median 676  $\mu\text{g/l}$ ) followed by patients with moderate fibrosis (466  $\mu\text{g/l}$ ) (Kruskal-Wallis one-way ANOVA on ranks between the four different groups of fibrosis,  $p < 0.001$ ). Moreover, patients with slight fibrosis had significantly elevated serum YKL-40 compared with patients with no fibrosis (270 vs. 174  $\mu\text{g/l}$ ,  $p=0.018$ ). Serum PIIINP and hyaluronan concentrations were also highest in patients with severe or moderate fibrosis. These two biochemical markers could also discriminate between patients with slight fibrosis and patients without fibrosis (serum PIIINP: 5.9 vs. 5.0  $\mu\text{g/l}$ ,  $p=0.021$ ; serum hyaluronan: 42.0 vs. 27.5  $\mu\text{g/l}$ ,  $p=0.005$ ). However, the median serum hyaluronan level was normal in both patients without fibrosis and pa-

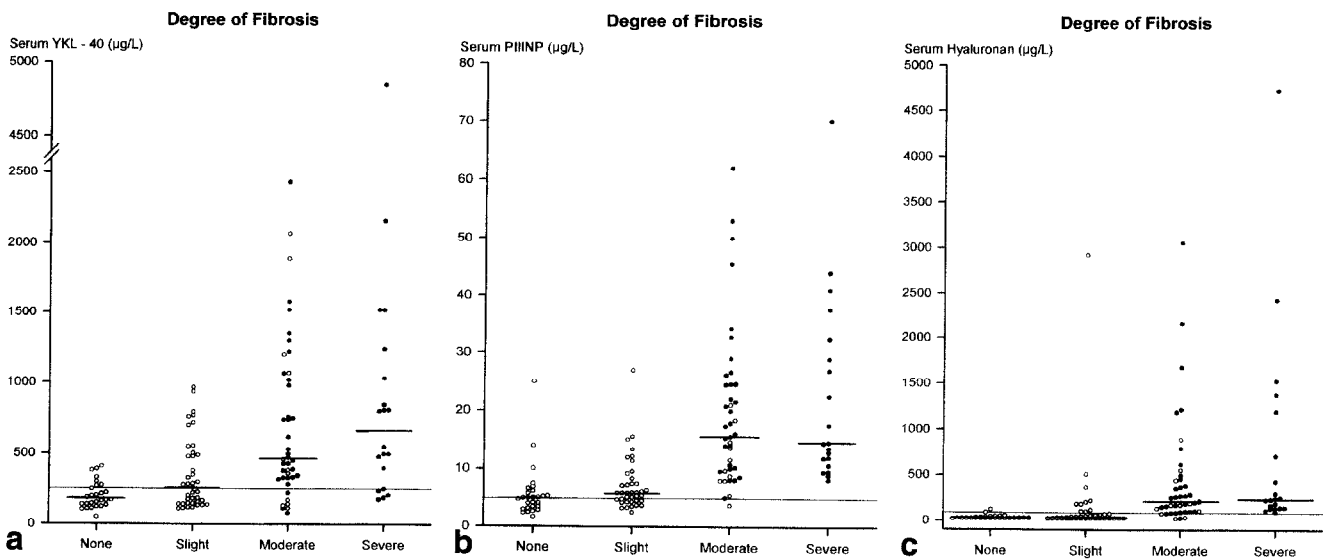


Fig. 2. Serum concentrations of YKL-40 (a), PIIINP (b), and hyaluronan (c) in patients with liver diseases and different histological degree of liver fibrosis. The definition of liver fibrosis grade is described in the Methods section. The bars represent median values. The horizontal lines represent the upper limit (95th percentile) of the normal range of serum YKL-40 (247  $\mu\text{g/l}$ ), serum PIIINP (5.4  $\mu\text{g/l}$ ) and serum hyaluronan (97  $\mu\text{g/l}$ ). (●) patients with alcoholic cirrhosis. (○) all other patients.

TABLE 3

Correlation between serum YKL-40, PIIINP, hyaluronan and parameters of liver function in patients with liver disease

	Serum YKL-40 ( $\mu\text{g/l}$ )	Serum PIIINP ( $\mu\text{g/l}$ ) Spearman's rho	Serum hyaluronan ( $\mu\text{g/l}$ )
Serum PIIINP ( $\mu\text{g/l}$ )	0.44***	–	0.81***
Serum hyaluronan ( $\mu\text{g/l}$ )	0.57***	0.81***	–
Serum aspartate aminotransferase (U/l)	0.34***	0.34***	0.28**
Serum alkaline phosphatase (U/l)	0.32***	0.49***	0.48***
Serum bilirubin ( $\mu\text{mol/l}$ )	0.22	0.42***	0.44***
Serum albumin ( $\mu\text{mol/l}$ )	–0.52***	–0.52***	–0.69***
Coagulation factors II, VII, and X	–0.25**	–0.36***	–0.49***

Values are Spearman's rho: \*\*  $p < 0.01$ , \*\*\*  $p < 0.001$ . PIIINP=N-terminal propeptide of type III procollagen.

TABLE 4

Relationship between the expression of YKL-40 in liver biopsies and the degree of liver fibrosis and fibrogenesis

	Fibrosis			Fibrogenesis		
	No $n=14$	Slight $n=29$	Moderate/Severe $n=49$	No $n=16$	Slight $n=32$	Moderate/Severe $n=44$
No YKL-40 staining	22%	14%	10%	44%	3%	9%
Slight YKL-40 staining	57%	59%	33%	50%	72%	23%
Moderate to Intense YKL-40 staining	21%	27%	57%	6%	25%	68%

The values shown represent the percentage value of sections with a YKL-40 staining score (no, slight or moderate/intense) out of the total number of sections described with no fibrosis, slight fibrosis or moderate/severe fibrosis and no fibrogenesis, slight fibrogenesis or moderate/severe fibrogenesis (as defined in "Materials and Methods").

tients with slight fibrosis and the percentage number of patients with elevated serum PIIINP in patients without fibrosis was 56% compared with 79% of the patients with slight fibrosis.

The degree of liver fibrosis was also treated as an ordinal variable with four categories and it was related to serum YKL-40, PIIINP and hyaluronan through a proportional odds regression model for ordinal data (23). When evaluated separately, each marker was found to predict the stage of fibrosis better when it was transformed to logarithms. In a multiple regression model, all logarithmically transformed markers were found to contribute with independent information (all significant at a 1% level) of the degree of liver fibrosis and the odds ratios (OR) corresponding to a doubling of each marker were: hyaluronan (OR=1.5, 95% confidence limits=1.1–2.1); YKL-40 (OR=1.7, 95% confidence limits=1.2–2.4); and PIIINP (OR=2.3, 95% confidence limits=1.4–3.8).

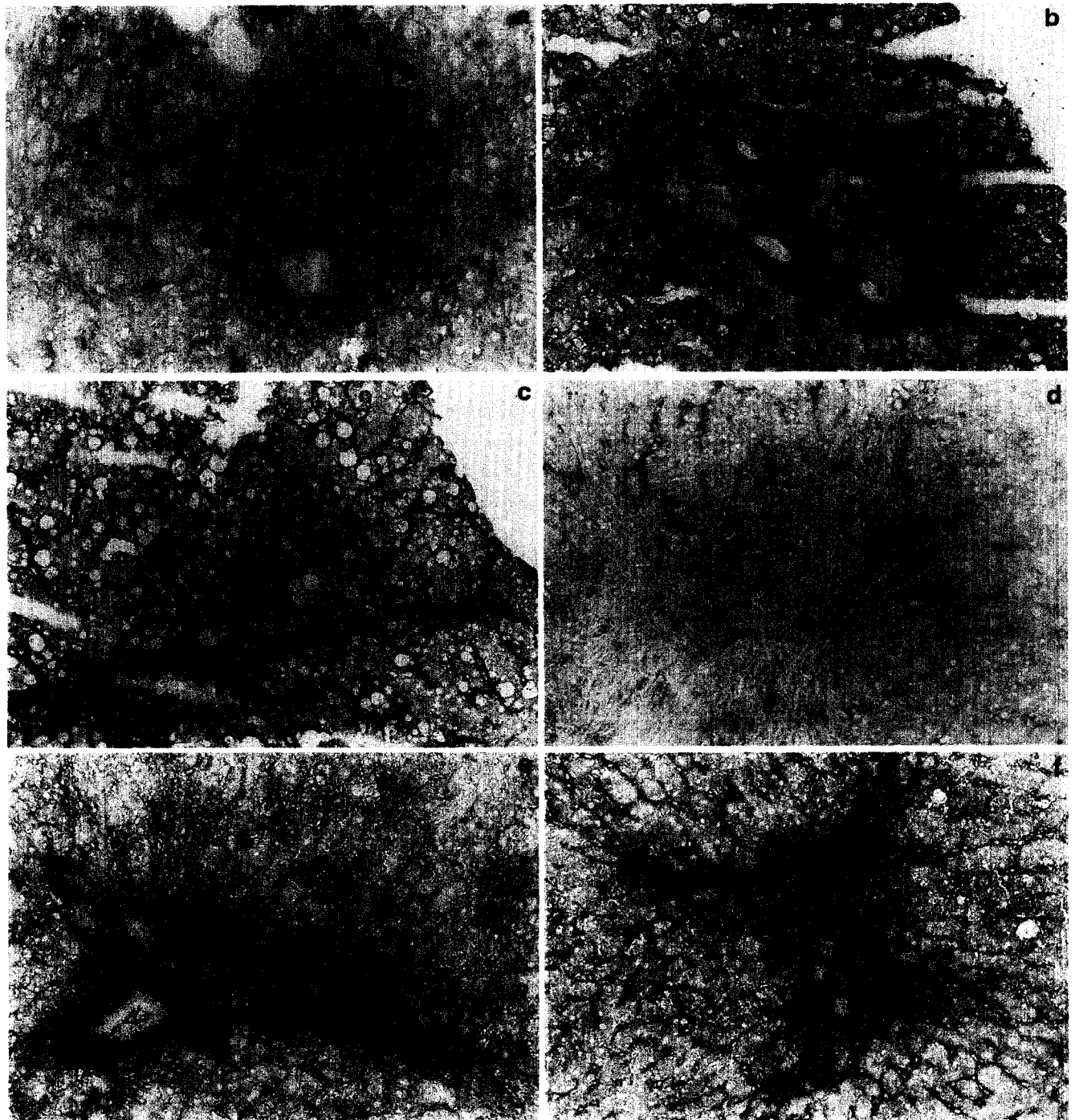
Table 3 shows the relationship between serum YKL-40, PIIINP, hyaluronan and the biochemical liver function tests. High correlations were found between serum PIIINP and serum hyaluronan ( $\rho=0.81$ ,  $p < 0.001$ ) and between serum YKL-40 and serum hyaluronan ( $\rho=0.57$ ,  $p < 0.001$ ). Serum YKL-40 correlated also (albeit with lower correlation coefficients) with serum PIIINP, alkaline phosphatase, aspartate aminotrans-

ferase and inversely with serum albumin and coagulation factors II, VII, X index.

#### Immunohistochemical investigation

Positive staining for YKL-40 was never detected in hepatocytes or in the connective tissue of normal liver (Fig. 3a). In biopsies from patients with liver disease staining for YKL-40 antigen was found in areas with slight fibrosis either pericellular or perisinusoidal, in areas with moderate or severe fibrosis, and along the fibrotic septa in association with areas of fibrogenesis (Fig. 3b and 3c). If the fibrotic septa consisted only of old mature collagen without signs of fibrogenesis, then no expression of the YKL-40 antigen was detected (Fig. 3d). In some patients with "fatty liver" positive staining for YKL-40 antigen was found in the connective tissue around the portal tract. In patients with chronic active hepatitis C virus, intense staining for YKL-40 was detected in areas with piecemeal necroses, but not in areas with lymphocytes (Fig. 3e). In all liver biopsies with fibrosis and/or fibrogenesis YKL-40 staining was found in extracellular areas free of cells as well as in cellular areas. In cellular areas it was not possible to discriminate the extent to which staining was intracellular.

The relationship between the staining of YKL-40 in liver biopsies and the degree of liver fibrosis and fibro-



*Fig. 3. Representative light micrographs of immunohistochemical staining of YKL-40 in six cryostat liver biopsies stained with an affinity-purified polyclonal rabbit antibody against human YKL-40. a) normal liver (serum YKL-40=105  $\mu$ g/l): no staining for YKL-40 in hepatocytes and slight positive staining for YKL-40 is limited to mesenchymal structures within the portal tract. b) non-cirrhotic liver fibrosis (205  $\mu$ g/l): positive staining for YKL-40 in areas with fibrosis along the portal tracts. c) alcoholic cirrhosis with fibrogenesis and alcoholic hepatitis (2160  $\mu$ g/l): intense staining for YKL-40 in areas with active fibrogenesis and slight staining along the sinusoids. d) inactive alcoholic cirrhosis (532  $\mu$ g/l): slight YKL-40 staining on the surface of the fibrotic septa and no staining inside the septa with mature collagen. e) chronic active hepatitis C virus (175  $\mu$ g/l): staining for YKL-40 in areas with fibrosis along the portal tracts and in areas with piecemeal necrosis. f) liver necrosis in a patient with forward failure (490  $\mu$ g/l): strong YKL-40 staining in areas with neutrophils and necrosis. All are magnification  $\times 250$ .*

genesis in the same biopsies are presented in Table 4. Ninety percent of the biopsies with moderate to severe fibrosis had either slight YKL-40 (33%) or moderate to intense YKL-40 staining (57%). Eighty-six percent of the biopsies with slight fibrosis had positive staining for YKL-40 antigen (59% had slight and 27% had moderate/intense YKL-40 staining). More than 90% of the biopsies with fibrogenesis had staining of YKL-40 in the areas with fibrogenesis.

## Discussion

Our present findings confirm that serum YKL-40 concentration is increased in patients with chronic liver disease. Most of the patients with alcoholic cirrhosis or posthepatic cirrhosis had elevated serum YKL-40, and the highest levels were found in patients with alcoholic cirrhosis in combination with alcoholic hepatitis. These patients had a median level of serum YKL-40 which was 3-fold higher than the upper normal level, and many had more than 5-fold elevated serum YKL-40. Patients with non-cirrhotic fibrosis had serum YKL-40 levels ranging from the normal range to highly increased levels as found in cirrhosis. Serum YKL-40 was closely related to the degree of fibrosis determined histologically with the highest levels in patients with moderate to severe fibrosis. Serum YKL-40 was elevated to a lesser extent in patients with slight fibrosis, but this elevation was still significantly greater than that seen in patients with no fibrosis.

We also investigated the localisation of YKL-40 in cryostat liver biopsy specimens using immunohistochemical staining. Positive staining for YKL-40 was found in the extracellular matrix in the fibrotic liver, but was not found in hepatocytes or in normal liver. A relation was found between the degree of positive staining of YKL-40 and the degree of liver fibrosis and fibrogenesis in the same biopsy. Patients with slight fibrosis had positive staining of YKL-40 in the areas of increased connective tissue around the portal tracts. In liver biopsies demonstrating alcoholic cirrhosis in combination with alcoholic hepatitis, an intense staining of the YKL-40 antigen was found in areas with ongoing fibrogenesis. No staining for YKL-40 was found in the old mature fibrotic septa, which lacked signs of fibrogenesis. These findings suggest that variations in serum YKL-40 are independent of liver disease aetiology but depend on the degree of liver fibrosis and ongoing fibrogenesis.

Low correlations were found between serum YKL-40 and serum alkaline phosphatase or serum aspartate aminotransferase, and low inverse correlations with serum albumin and the coagulation factors. Serum albumin and coagulation factors, etc. reflect the func-

tion of the hepatocytes but may also indirectly reflect the degree of fibrosis, since perisinusoidal capillarization creates a diffusion barrier which limits the export of proteins synthesised by hepatocytes. The highest correlation coefficients were found between serum YKL-40 and serum hyaluronan and serum PIIINP. Hyaluronan is a polysaccharide found in virtually all connective tissues (24) and in liver fibrosis hyaluronan is a component of the extracellular matrix. PIIINP is the N-terminal cleavage product of the conversion of procollagen III into collagen III that is a component of the extracellular matrix in liver fibrosis. In the liver both PIIINP and hyaluronan are synthesised by the hepatic stellate cells and metabolised in the endothelial liver cells (24–27). In accordance with other studies we found increased serum levels of PIIINP and hyaluronan in most patients with cirrhosis (28–41). Serum hyaluronan was normal in patients with fatty liver and non-cirrhotic fibrosis, whereas serum PIIINP levels were increased in 45% and 79% of these patients, respectively. Multiple regression analysis showed that serum YKL-40, PIIINP and hyaluronan contributed with independent information of the degree of liver fibrosis.

Our results indicate that serum YKL-40 provides information on fibrosis and fibrogenesis that is different from that of serum PIIINP and serum hyaluronan. Serum YKL-40 is significantly elevated in the subset of alcoholic cirrhotic patients who also have alcoholic hepatitis, while serum PIIINP and hyaluronan are not. Furthermore, the serum YKL-40 concentration appears to be the best of the three serological markers in discriminating between patients with slight fibrosis and patients with no fibrosis. This indicates that serum YKL-40 may be a better marker for early stages of fibrosis and ongoing fibrogenesis. We have earlier reported that YKL-40 is released from the hepatosplanchnic system (17). This is in contrast to serum PIIINP and hyaluronan where a hepato-splanchnic extraction is found both in patients with normal liver function and in patients with alcoholic liver disease (29,38). The high serum PIIINP and hyaluronan levels observed in patients with cirrhosis may therefore arise in part from increased synthesis at sites of fibrosis and in part from decreased catabolism secondary to liver dysfunction and decreased function of the endothelial sinusoidal cell.

The cellular sources of YKL-40 in the liver are unknown. We think that hepatic stellate cells are possibly a source of secreted YKL-40 during active hepatic fibrogenesis. These cells play a central role in liver fibrosis (42–44) and are found in the space of Disse in close contact with hepatocytes and endothelial cells.

Most of the extracellular matrix proteins (collagens, non-collagenous structural glycoproteins, glycosaminoglycans, proteoglycans, and elastin) and the degradative metalloproteinases are synthesised by the hepatic stellate cells during the development of liver fibrosis (3,42–44). Furthermore, the hepatic stellate cells are functionally and morphologically related to cells (42–44) that have been shown to secrete YKL-40, like smooth muscle cells (12) and myofibroblasts (Johansen JS, personal observation). In some instances YKL-40 may also be secreted by macrophages at a late stage of differentiation (7,13,15) and by activated neutrophils (16). We found intense expression of the YKL-40 antigen in areas with liver necrosis and alcoholic hepatitis and in these cases YKL-40 may also originate from activated neutrophils and macrophages.

The biological function of YKL-40 is unknown. The protein is produced in a wide variety of cell types and in particular from cells located in tissues with increased remodelling/degradation or inflammation of the extracellular matrix (4,5,7,9,11,12,15,16). Due to its chitin- and heparin-binding properties (12,13), YKL-40 may have a function in adhesion of cells to extracellular matrix proteins and it may have a role in tissue remodelling and cell migration. Chitin is not found in mammals, and no studies have been able to demonstrate chitinase or hyaluronidase activity of YKL-40 (5,6,13). Recently, a vertebrate synthase has been identified (45–47) which is supposed to create short chitin stretches that are essential to initiate hyaluronan synthesis (46). It is possible that YKL-40 recognise hyaluronan precursor as a substrate and interfere with its synthesis, which could affect local hyaluronan levels. One physiological ligand for the heparin binding site in YKL-40 could be perlecan, which is the major heparan sulphate proteoglycan of basement membranes and is also expressed in the extracellular matrix (48). Perlecan is known to be involved in cell migration and proliferation and in adhesion of cells to extracellular matrix molecules. Studies have shown that perlecan can store, activate or inactivate growth factors and cytokines which play important roles in fibrogenesis (48). Human hepatic stellate cells and endothelial cells express perlecan, whereas hepatocytes and Kupffer cells do not (49–51). Immunohistochemical studies have demonstrated staining for perlecan in normal human liver in the sinusoids and the blood vessels of the portal tracts (49,50). In damaged rat liver with cirrhosis, positive perlecan staining was found in the perisinusoidal area, in the fibrotic septa and in necrotic areas (51), i.e. the pattern of positive staining for YKL-40 in cirrhotic liver is found in the same areas as perlecan.

In summary, the results of the present study indicate

that the serum concentration of YKL-40 may provide new information of the amount of liver fibrosis and ongoing fibrogenesis in patients with liver diseases. Future longitudinal studies should evaluate if serum YKL-40 in combination with other serological markers, like serum PIIINP, serum hyaluronan and the metalloproteinases, can be of value in the detection of (alcoholic) patients who have a high risk for progression from fatty liver to more severe liver damage, in particular early fibrosis.

### Acknowledgements

The expert technical assistance of Margit Bech and Vibeke Karlsen, Department of Pathology, Hvidovre Hospital, Denmark and Birgitte Olsen, Institute of Medical Anatomy Section A, The Panum Institute, University of Copenhagen, Denmark is gratefully acknowledged. We also appreciate helpful support from Hanne Hansen, Department of Clinical Physiology and Nuclear Medicine, Hvidovre Hospital, Denmark in the statistical calculations and the preparation of the figures, and from Lene Theil Skovgaard, Department of Biostatistics, University of Copenhagen, Denmark, in the statistical analysis.

The study was supported by grants from the “Dagmar Marshalls Foundation”, the “Danish Foundation for the Advancement of Medical Science”, the “Danish Hospital Foundation for Medical Research, Region of Copenhagen, The Faroe Islands and Greenland”, “Michaelsen Fonden” and “Overlæge Johan Boserup og Lise Boserups Legat”.

### References

1. Bissell DM, Roll J. Connective tissue metabolism and hepatic fibrosis. In: Zakim D, Boyer TD, editors. *Hepatology*. Philadelphia, London, Toronto: W.B. Saunders Company; 1990. p. 424–44.
2. Friedman SL. The cellular basis of hepatic fibrosis. Mechanisms and treatment strategies. *N Engl J Med* 1993; 328: 1828–35.
3. Gressner AM. Liver fibrosis: perspectives in pathobiochemical research and clinical outlook. *Eur J Clin Chem Clin Biochem* 1991; 29: 293–311.
4. Johansen JS, Jensen HS, Price PA. A new biochemical marker for joint injury. Analysis of YKL-40 in serum and synovial fluid. *Br J Rheumatol* 1993; 32: 949–55.
5. Hakala BE, White C, Recklies AD. Human cartilage gp-39, a major secretory product of articular chondrocytes and synovial cells, is a mammalian member of a chitinase protein family. *J Biol Chem* 1993; 268: 25803–10.
6. Hu B, Trinh K, Figueira WF, Price PA. Isolation and sequence of a novel human chondrocyte protein related to mammalian members of the chitinase protein family. *J Biol Chem* 1996; 271: 19415–20.
7. Krause SW, Rehli M, Kreutz M, Schwarzfischer L, Paulauskis JD, Andreesen R. Differential screening identifies genetic markers of monocyte to macrophage maturation. *J Leukoc Biol* 1996; 60: 540–5.
8. Rejman JJ, Hurley WL. Isolation and characterization of a novel



- 39 kilodalton whey protein from bovine mammary secretions collected during the nonlactating period. *Biochem Biophys Res Commun* 1988; 150: 329–34.
9. Nyirkos P, Golds EE. Human synovial cells secrete a 39 kDa protein similar to a bovine mammary protein expressed during the non-lactating period. *Biochem J* 1990; 268: 265–8.
  10. Johansen JS, Williamson MK, Rice JS, Price PA. Identification of proteins secreted by human osteoblastic cells in culture. *J Bone Miner Res* 1992; 7: 501–12.
  11. Morrison BW, Leder P. *neu* and *ras* initiate murine mammary tumors that share genetic markers generally absent in *c-myc* and *int-2*-initiated tumors. *Oncogene* 1994; 9: 3417–26.
  12. Shackleton LM, Mann DM, Millis AJT. Identification of a 38-kDa heparin-binding glycoprotein (gp38k) in differentiating vascular smooth muscle cells as a member of a group of proteins associated with tissue remodeling. *J Biol Chem* 1995; 270: 13076–83.
  13. Renkema GH, Boot RG, Au FL, Donker-Koopman WE, Strijland A, Muijsers AO, et al. Chitotriosidase, a chitinase, and the 39-kDa human cartilage glycoprotein, a chitin-binding lectin, are homologues of family 18 glycosyl hydrolases secreted by human macrophages. *Eur J Biochem* 1998; 251: 504–9.
  14. Verheijden GFM, Rijnders AWM, Bos E, Coenen-de Roo CJJ, Van Staveren CJ, Miltenburg AMM, et al. Human cartilage glycoprotein-39 as a candidate autoantigen in rheumatoid arthritis. *Arthritis Rheum* 1997; 40: 1115–25.
  15. Rehli M, Krause SW, Andreesen R. Molecular characterization of the gene for human cartilage gp-39 (CHI3L1), a member of the chitinase protein family and marker for late stage macrophage differentiation. *Genomics* 1997; 43: 221–5.
  16. Volck B, Price PA, Johansen JS, Sørensen O, Benfield T, Nielsen HJ, et al. YKL-40, a mammalian member of the bacterial chitinase family, is a matrix protein of specific granules in human neutrophils. *Proc Assoc Am Assoc Physician* 1998; 110: 351–60.
  17. Johansen JS, Møller S, Price PA, Bendtsen F, Junge J, Garbarsch C, et al. Plasma YKL-40: a new potential marker of fibrosis in patients with alcoholic cirrhosis? *Scand J Gastroenterol* 1997; 32: 582–90.
  18. Menghini G. One-second biopsy of the liver – problems of its clinical application. *N Engl J Med* 1970; 283: 582–5.
  19. Poulsen H, Christoffersen P. *Atlas of Liver Biopsies*. Copenhagen: Munksgaard; 1979.
  20. Johansen JS, Hvolris J, Hansen M, Backer V, Lorenzen I, Price PA. Serum YKL-40 levels in healthy children and adults. Comparison with serum and synovial fluid levels of YKL-40 in patients with osteoarthritis or trauma of the knee joint. *Br J Rheumatol* 1996; 35: 553–9.
  21. Risteli J, Niemi S, Trivedi P, Mentausta O, Mowat AP, Risteli L. Rapid equilibrium radioimmunoassay for the amino-terminal propeptide of human type III procollagen. *Clin Chem* 1988; 34: 715–8.
  22. Brandt R, Hedlöf E, Åsman I, Bucht A, Tengblad A. A convenient radiometric assay for hyaluronan. *Acta Otolaryngol (Stockholm)* 1987; 442 (Suppl): 31–5.
  23. McCullagh P, Nelder JA. *Generalized Linear Models*. 2nd ed. London: Chapman and Hall; 1989.
  24. Laurent TC, Fraser JRE. Hyaluronan. *FASEB J* 1992; 6: 2397–404.
  25. Gressner AM, Scafer S. Comparison of sulphated glycosaminoglycan and hyaluronate synthesis and secretion in cultured hepatocytes, fat storing cells, and Kupffer cells. *J Clin Chem Clin Biochem* 1989; 27: 141–9.
  26. Smedsrød B, Pertoft H, Eriksson S, Fraser JRE, Laurent TC. Studies *in vitro* on the uptake and degradation of sodium hyaluronate in rat liver endothelial cells. *Biochem J* 1984; 223: 617–26.
  27. Smedsrød B. Amino-terminal propeptide of type III procollagen is cleared from the circulation by receptor-mediated endocytosis in liver endothelial cells. *Collagen Rel Res* 1988; 8: 375–88.
  28. Engström-Laurent A, Loof L, Nyberg A, Schröder T. Increased serum levels of hyaluronate in liver disease. *Hepatology* 1985; 5: 638–42.
  29. Henriksen JH, Bentsen KD, Laurent TC. Splanchnic and renal extraction of circulating hyaluronan in patients with alcoholic liver disease. *J Hepatol* 1988; 6: 158–66.
  30. Gibson PR, Fraser JRE, Brown TJ, Finch CF, Jones PA, Colman JC, et al. Hemodynamic and liver function predictors of serum hyaluronan in alcoholic liver disease. *Hepatology* 1992; 15: 1054–9.
  31. Guechot J, Poupon RE, Giral P, Balkau B, Giboudeau J, Poupon R. Relationship between procollagen III aminoterminal propeptide and hyaluronan serum levels and histological fibrosis in primary biliary cirrhosis and chronic viral hepatitis C. *J Hepatol* 1994; 20: 388–93.
  32. Pares A, Deulofeu R, Gimenez A, Caballeria L, Bruguera M, Caballeria J, et al. Serum hyaluronate reflects hepatic fibrogenesis in alcoholic liver disease and is useful as a marker of fibrosis. *Hepatology* 1996; 24: 1399–403.
  33. Bentsen KD, Horn T, Risteli J, Risteli L, Engström-Laurent A, Hørslev-Petersen K, et al. Serum aminoterminal type III procollagen peptide and the 7S domain of type IV collagen in patients with alcohol abuse. Relation to ultrastructural fibrosis in the acinar zone 3 and to serum hyaluronan. *Liver* 1987; 7: 339–46.
  34. Ramadori G, Zöhrens G, Manns M, Rieder H, Dienes HP, Hess G, et al. Serum hyaluronate and type III procollagen aminoterminal propeptide concentration in chronic liver disease. Relationship to cirrhosis and disease activity. *Eur J Clin Invest* 1991; 21: 323–30.
  35. Hayasaka A, Schuppan D, Ohnishi K, Okuda K, Hahn EG. Serum concentrations of the carboxyterminal cross-linking domain of procollagen type IV (NCl) and the aminoterminal propeptide of procollagen type III (PIIP) in chronic liver disease. *J Hepatol* 1990; 10: 17–22.
  36. Shahin M, Schuppan D, Waldherr R, Risteli J, Risteli L, Savolainen E-R, et al. Serum procollagen peptides and collagen type VI for the assessment of activity and degree of hepatic fibrosis in schistosomiasis and alcoholic liver disease. *Hepatology* 1992; 15: 637–44.
  37. Colombo M, Annoni G, Donato MF, Conte D, Martinez D, Zaramella MG, et al. Serum type III procollagen peptide in alcoholic liver disease and idiopathic hemochromatosis: its relationship to hepatic fibrosis, activity of the disease and iron overload. *Hepatology* 1985; 5: 475–9.
  38. Bentsen KD, Henriksen JH, Bendtsen F, Hørslev-Petersen K, Lorenzen I. Splanchnic and renal extraction of circulating type III procollagen aminoterminal propeptide in patients with normal liver function and in patients with alcoholic cirrhosis. *Hepatology* 1990; 11: 957–63.
  39. Trinchet J-C, Hartmann DJ, Pateron D, Laarif M, Gallard P, Ville G, et al. Serum type I collagen and N-terminal peptide of type III procollagen in chronic hepatitis: relationship to liver histology and conventional liver tests. *J Hepatol* 1991; 12: 139–44.
  40. Savolainen ER, Goldberg B, Leo MA, Velez M, Lieber CS. Diagnostic value of serum procollagen peptide measurements in alcoholic liver disease. *Alcohol Clin Exp Res* 1984; 8: 384–9.
  41. Torres-Salines M, Pares A, Caballeria J, Jimenez W, Heredia D, Bruguera M, et al. Serum procollagen type III peptide as a marker of hepatic fibrogenesis in alcoholic hepatitis. *Gastroenterology* 1986; 90: 1241–6.
  42. Pinzani M, Marra F, Carloni V. Signal transduction in hepatic stellate cells (review article). *Liver* 1998; 18: 2–13.
  43. Iredale JP. Matrix turnover in fibrogenesis [review]. *Hepato-Gastroenterology* 1996; 43: 56–71.
  44. Mathew J, Geerts A, Burt AD. Pathobiology of hepatic stellate cells [review]. *Hepato-Gastroenterology* 1996; 43: 72–91.
  45. Semino CE, Specht CA, Raimondi A, Robbins PW. Homologs of the *Xenopus* developmental gene DG42 are present in zebrafish and mouse and are involved in the synthesis of Nod-like chitin oligosaccharides during early embryogenesis. *Proc Natl Acad Sci USA* 1996; 93: 4548–53.
  46. Meyer MF, Kreil G. Cells expressing the DG42 gene from early *Xenopus* embryos synthesize hyaluronan. *Proc Natl Acad Sci USA* 1996; 93: 4543–7.

47. Varki A. Does DG42 synthesize hyaluronan or chitin? A controversy about oligosaccharides in vertebrate development. *Proc Natl Acad Sci USA* 1996; 93: 4523–5.
48. Iozzo RV, Cohen IR, Grässel S, Murdoch AD. The biology of perlecan: the multifaceted heparan sulphate proteoglycan of basement membranes and pericellular matrices. *Biochem J* 1994; 302: 625–39.
49. Roskams T, Moshage H, de Vos R, Guido D, Yap P, Desmet V. Heparan sulfate proteoglycan expression in normal human liver. *Hepatology* 1995; 21: 950–8.
50. Murdoch AD, Liu B, Schwarting R, Tuan RS, Iozzo RV. Widespread expression of perlecan proteoglycan in basement membranes and extracellular matrices of human tissues as detected by a novel monoclonal antibody against domain III and by *in situ* hybridization. *J Histochem Cytochem* 1994; 42: 239–49.
51. Gallai M, Kovalszky I, Knittel T, Neubauer K, Armbrust T, Ramadori G. Expression of extracellular matrix proteoglycans perlecan and decorin in carbon-tetrachloride-injured rat liver and in isolated liver cells. *Am J Pathol* 1996; 148: 1463–71.